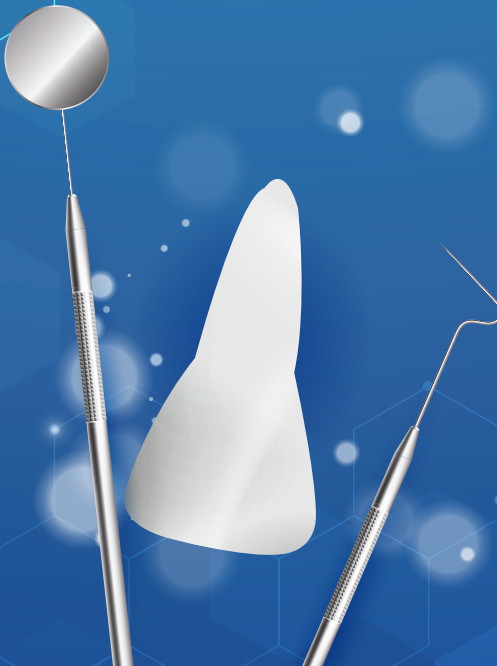



ORAL HEALTH PROGRAMME  
MINISTRY OF HEALTH MALAYSIA

# MANAGEMENT OF **AVULSED PERMANENT ANTERIOR TEETH**

(3<sup>RD</sup> EDITION)



DECEMBER  
2019



**Published by:**

Oral Health Technology Section  
Oral Health Programme  
Ministry of Health Malaysia  
Level 5, Block E10, Precinct 1  
Federal Government Administrative Centre  
62590 Putrajaya, Malaysia

**Copyright**

The copyright owner of this publication is Oral Health Programme (OHP), Ministry of Health Malaysia. Content may be reproduced in any number of copies and in any format or medium provided that a copyright acknowledgement to OHP is included and the content is not changed, not sold, nor used to promote or endorse any product or service and not used inappropriately or misleading context.

ISBN: 978-967-16632-5-7

Available on the following websites:

<http://www.moh.gov.my>

<http://www.ohd.gov.my>

<http://www.acadmed.org.my>

Also available as an app for Android and iOS platform: MyMaHTAS

**STATEMENT OF INTENT**

These guidelines update and supplant the previous guidelines developed in 2010 and are based on the best available contemporary evidence. They are intended as a guide for the best clinical practice in the management of avulsed permanent anterior teeth presently. However, it must be noted that adherence to these guidelines do not necessarily lead to the best clinical outcome in individual patient care, as every health care provider is responsible for the management of his/her unique patient based on the clinical presentation and management options available locally.

**REVIEW OF THE GUIDELINES**

These guidelines were issued in December 2019 and will be reviewed in 2024 or earlier if important new evidence becomes available. When it is due for updating, the head of related specialty will be informed about it. A multidisciplinary team will be formed and discussion will be done on the need for a revision including the scope of the revised CPG. The systematic review methodology used by the Malaysia Health Technology Assessment Section (MaHTAS) will be employed in review of the guidelines.

Every care is taken to ensure that this publication is correct in every detail at the time of publication. However, in the event of errors or omissions, corrections will be published in the web version of this document, which is the definitive version at all times.

<b>TABLES OF CONTENTS</b>		<b>Page</b>
LEVELS OF EVIDENCE		i
GUIDELINES DEVELOPMENT		i
OBJECTIVES, CLINICAL QUESTIONS AND TARGET POPULATION		iii
TARGET GROUP / USER AND SETTINGS		iii
DEVELOPMENT GROUP		v
REVIEWERS		vi
ALGORITHM:		
• Management of Avulsed Permanent Anterior Tooth (At the Site of Incident)		viii
• Management of Avulsed Permanent Anterior Tooth (Immature Root) At the Dental Clinic		ix
Management of Avulsed Permanent Anterior Tooth (Mature Root) At the Dental Clinic		x
LIST OF KEY MESSAGES		xi
LIST OF RECOMMENDATIONS		xii
1.	INTRODUCTION	1
2.	EMERGENCY MANAGEMENT AT SITE OF INCIDENTS	2
3.	CONTRAINDICATIONS FOR REPLANTATION	4
4.	CLINICAL MANAGEMENT	5
	4.1 Informed Consent	5
	4.2 Pre-operative Assessment	5
	4.3 Imaging	5
	4.4 Replantation Technique	6
	4.5 Splinting Technique	7
	4.6 Post-operative Care	7
5.	PROGNOSTIC FACTORS	7
	5.1 Extra-alveolar Time	8
	5.2 Storage Medium	8
	5.3 Tooth Maturity	10
	5.4 Root Canal Treatment	10
	5.5 Contamination of Root Surface	13
	5.6 Type and Duration of Splinting	14
	5.7 Root Surface Treatment	15
	5.8 Systemic Antibiotics	15
6.	FOLLOW-UP AND MONITORING	15
	6.1 Follow-up Intervals	16
	6.2 Complications of Replanted Avulsed Permanent Anterior Tooth	17

<b>TABLES OF CONTENTS</b>		<b>Page</b>
7.	MANAGEMENT OF COMPLICATIONS	18
	7.1 Pulp Necrosis and Inflammatory Root Resorption	18
	7.2 Replacement Root Resorption and Ankylosis	19
	7.3 Tooth Loss (Interim & Long-term Treatment Options)	21
8.	IMPLEMENTING THE GUIDELINES	22
	8.1 Facilitating and Limiting Factors	23
	8.2 Potential Resource Implications	23
	8.3 Proposed Clinical Audit Indicators	24
	REFERENCES	25
	APPENDIX 1: Search Strategy	32
	APPENDIX 2: Clinical Questions	33
	APPENDIX 3: Main characteristics, efficacy and accessibility of each storage medium for avulsed permanent anterior teeth	34
	APPENDIX 4: Dental Trauma Data Collection Form	35
	APPENDIX 5: Clinical and radiographic parameters to be recorded during review appointment	37
	APPENDIX 6: Possible complications and expected timing of occurrence following replantation of avulsed permanent anterior teeth.	38
	ACKNOWLEDGEMENTS, DISCLOSURE STATEMENT AND SOURCES OF FUNDING	39

## LEVELS OF EVIDENCE

LEVEL	STUDY DESIGN
I	Evidence obtained from at least one properly designed randomised controlled trial.
II-1	Evidence obtained from well-designed controlled trials without randomisation.
II-2	Evidence obtained from well-designed cohort or case-control analytic studies, preferably from more than one centre or research group.
II-3	Evidence obtained from multiple time series studies, with or without intervention. Dramatic results in uncontrolled experiments (such as the results of the introduction of penicillin treatment in the 1940s) could also be regarded as this type of evidence.
III	Opinions or respected authorities, based on clinical experience; descriptive studies and case reports; or reports of expert committees.

Source: Adapted from Harris RP, Helfand M, Woolf SH, Lohr KN, Mulrow CD, Teutsch SM, Atkins D. Current Methods of the U.S. Preventive Services Task Force: A Review of the Process. Am J Prev Med. 2001;20 (suppl 3):21-35.

## GUIDELINES DEVELOPMENT

These clinical practice guidelines (CPG) were developed by an expert committee consisting of Paediatric Dental Specialists, Dental Public Health Specialists, a Restorative Dental Specialist, Dental Officers and a Dental Therapist mainly from the Ministry of Health and the Ministry of Higher Education.

The previous edition of the CPG on Management of Avulsed Permanent Anterior Teeth in Children (November 2010) was used as the basis for the development of these guidelines. The recommendations were formulated taking into consideration the best available evidence and local practices. Several improvements have been introduced in this edition. The scope has been expanded to include management of all avulsed permanent anterior teeth. In addition, new and updated information have been included in these guidelines. Besides this, clinical audit indicators have also been identified for the purpose of monitoring and evaluating outcomes.

Literature search was carried out using the following electronic databases: Medline, Pubmed, Cochrane Database of Systemic Reviews (CDSR) and Embase while full text journal articles were retrieved from these databases.

The literature search was limited to human study, English language and published articles from inception of databases to June 2019. In addition, the reference lists of all retrieved literature and guidelines were searched to further identify relevant studies. Literature searches were repeated for all clinical questions at the end of the CPG development process allowing any relevant papers published to be included. Future CPG updates will consider evidence published after this cut-off date. The search strategy can be found in **Appendix 1**. The details of the search strategy can be obtained upon request from the CPG Secretariat.

There were eight (8) clinical questions which were assigned to members of the development group. The group members met a total of 10 times throughout the development of these guidelines. All retrieved literature were appraised by at least two members, presented in the form of evidence tables and discussed during group meetings. All statements and recommendations formulated were agreed upon by both the development group and reviewers. This CPG is based on the findings of systematic reviews, randomised controlled trials, observational studies, with local practices taken into consideration. However, when there was lack of evidence, recommendations were based on consensus of group members. Although ideally patients' views and preferences need to be considered in the development of CPGs, in this instance, it was not feasible.

The literature used in these guidelines were graded using the US/Canadian Preventive Services Task Force Level of Evidence (2001), while the formulation of recommendation was done using the principles of GRADE. The writing of the CPG strictly follows the requirements of Appraisal of Guidelines Research and Evaluation (AGREE II).

The draft was reviewed by a panel of internal and external reviewers. Recommendations were presented to the Technical Advisory Committee for CPGs, and finally to the HTA and CPG Council, Ministry of Health, Malaysia for approval.

## OBJECTIVE

To review and expand the scope of the existing guidelines and to provide evidence-based recommendations for best management practices of all avulsed permanent anterior teeth.

## SPECIFIC OBJECTIVES

1. To disseminate and reinforce knowledge on the management of avulsed permanent anterior teeth among healthcare professionals and the public.
2. To recommend current evidence-based management of all avulsed permanent anterior teeth, which encompasses the following aspects:
  - a. Emergency management at site of incidents.
  - b. Clinical management at the dental clinic.
  - c. Clinical management of outcome of replanted avulsed permanent anterior teeth during follow-up.

## CLINICAL QUESTIONS

The clinical questions addressed by these guidelines can be found in **Appendix 2**.

## TARGET POPULATION

These guidelines are applicable to all patients with avulsed permanent anterior teeth.

- i. Inclusion criteria
  - Patients with traumatically avulsed permanent anterior teeth



## ii. Exclusion criteria

- Patients with avulsed permanent anterior teeth associated with comminuted alveolar fractures
- Patients with avulsed permanent anterior teeth due to other causes than trauma such as periodontal disease and pathology

## TARGET GROUP / USER

1. All health care providers involved in the diagnosis and management of avulsed permanent anterior teeth namely:

a) Primary care providers

- Dental officers
- Medical officers
- Allied health professionals

b) Specialists of related disciplines

- Related dental specialists (i.e. Paediatric Dental Specialists, Orthodontists, Dental Public Health Specialists, Oral and Maxillofacial Surgeons, Periodontologists, Restorative Dental Specialists)
- Related medical specialists (i.e. Family Medicine Specialists, Accident and Emergency Physicians, and Anaesthetists)

2. Public

## SETTINGS

- Healthcare: Outpatient and inpatient settings in all healthcare facilities
- Site of incidents: e.g. schools, playground, swimming pool, home, residential area

## DEVELOPMENT GROUP

Chairperson	Secretary
<p><b>Dr Sarimah Mohd Mokhtar</b> Paediatric Dental Specialist Jabatan Pergigian Pediatrik Hospital Tuanku Ja'afar 70300 Seremban Negeri Sembilan</p>	<p><b>Dr Suriani Sukeri</b> Paediatric Dental Specialist Jabatan Pergigian Pediatrik Aras 3, Hospital Wanita dan Kanak-Kanak Lot 25, Jalan Raja Muda Abdul Aziz 50300 Kuala Lumpur</p>
Members	
<p><b>Dr Zakiah Muhammad</b> Dental Public Health Specialist Klinik Pergigian Besar Jalan Za'aba Jalan Zaaba 70100 Seremban Negeri Sembilan</p>	<p><b>Dr Ithnaniah Abdul Wahab</b> Restorative Dental Specialist Klinik Pakar Pergigian Restoratif Klinik Pergigian Komuniti Tanglin Jalan Cenderasari 50584 Kuala Lumpur</p>
<p><b>Dr Roziana Abdullah</b> Paediatric Dental Specialist Jabatan Pergigian Pediatrik Hospital Ampang Jalan Mewah Utara, Pandan Mewah 68000 Ampang Selangor</p>	<p><b>Dr Salleh Zakaria</b> Dental Public Health Specialist Program Kesihatan Pergigian KKM Aras 5 Blok E10 Kompleks E Presint 1 Pusat Pentadbiran Kerajaan Persekutuan 62590 WP Putrajaya</p>
<p><b>Dr Mohd Ridzuan Mohd Razi</b> Paediatric Dental Specialist Jabatan Pergigian Pediatrik Hospital Sultanah Aminah Jalan Persiaran Abu Bakar Sultan 80100 Johor Bahru Johor</p>	<p><b>Dr Ahmad Faisal Ismail</b> Lecturer &amp; Paediatric Dental Specialist Jabatan Pergigian Pediatrik Kuliyah Pergigian Universiti Islam Antarabangsa Malaysia (UIAM) Bandar Indera Mahkota 25200 Kuantan Pahang</p>
<p><b>Dr Suhailiza Saharudin</b> Paediatric Dental Specialist Jabatan Pergigian Pediatrik Hospital Raja Permaisuri Bainun Jalan Raja Ashman Shah 30450 Ipoh Perak</p>	<p><b>Dr Ameera Syafiqah Aly</b> Dental Officer Jabatan Komuniti Kesihatan Pergigian &amp; Pencegahan Klinikal Fakulti Pergigian Universiti Malaya 50603 Kuala Lumpur</p>
<p><b>Dr Noor Hasmin Mokhtar</b> Dental Officer Program Kesihatan Pergigian KKM Aras 5 Blok E10 Kompleks E Presint 1 Pusat Pentadbiran Kerajaan Persekutuan 62590 WP Putrajaya</p>	<p><b>Chitra Devi Subramaniam</b> Senior Dental Therapist Jabatan Pergigian Pediatrik Aras 3, Hospital Wanita dan Kanak-Kanak Lot 25, Jalan Raja Muda Abdul Aziz 50300 Kuala Lumpur</p>

## REVIEWERS (INTERNAL AND EXTERNAL)

These guidelines were reviewed by a panel of independent reviewers from both public and private sectors who were asked to comment primarily on the comprehensiveness and accuracy of interpretation of the evidence supporting the recommendations in this CPG. The following internal and external reviewers provided comments and feedbacks on the proposed draft:

### INTERNAL REVIEWERS

Col. (Dr) Zahani Mohamed Yusoff  
Pediatric Dental Specialist  
Hospital Angkatan Tentera Tuanku Mizan  
No 3, Jalan 4/27A, Seksyen 2,  
Wangsa Maju  
53300 Kuala Lumpur  
Malaysia

Dr Zuraidah Wahid  
Emergency Physician  
Jabatan Kecemasan dan Trauma  
Hospital Tuanku Jaafar  
Jalan Rasah  
70300 Seremban  
Negeri Sembilan, Malaysia

Dr Saadah Atan  
Pediatric Dental Specialist  
Jabatan Pergigian Pediatrik  
Hospital Melaka  
Jalan Mufti Haji Khalil  
75400 Melaka,  
Malaysia

Dr Abd Halim bin Abu Bakar  
Dental Officer  
Klinik Pergigian Chini,  
Klinik Kesihatan Chini  
26690 Chini  
Pahang, Malaysia

Dr Rasidah Ayob  
Consultant Periodontologist  
Unit Pakar Periodontik  
Klinik Pergigian Peringgit  
Jalan Pantai Peringgit  
75400 Peringgit  
Melaka, Malaysia

Dr Arilatha Arimuthu  
Restorative Dental Specialist  
Unit Pakar Restoratif  
Klinik Pergigian Bandar Seri Putra  
Jalan Seri Putra 1/9  
Bandar Seri Putra  
43000 Kajang  
Selangor, Malaysia

Assoc. Prof. Dr Siti Noor Fazliah Mohd Noor  
Associate Professor / Paediatric Dentistry Consultant  
Advanced Medical and Dental Institute  
Universiti Sains Malaysia  
Bertam, 13200 Kepala Batas  
Pulau Pinang, Malaysia

## EXTERNAL REVIEWERS

Dr Shahid Mitha  
Senior Assistant Professor  
PAPRSB Institute of Health Sciences  
Universiti Brunei Darussalam  
Jalan Tungku Link  
BE1410  
Brunei Darussalam

Dr Nazatul Sabariah Ahmad  
Consultant in Paediatric Dentistry  
Klinik Pergigian Dental Valet@Bangi  
8-15-01 & 8-17-01 (GF)  
Jalan Medan PB7A, Bangi Sentral  
43650 Bandar Baru Bangi  
Selangor, Malaysia

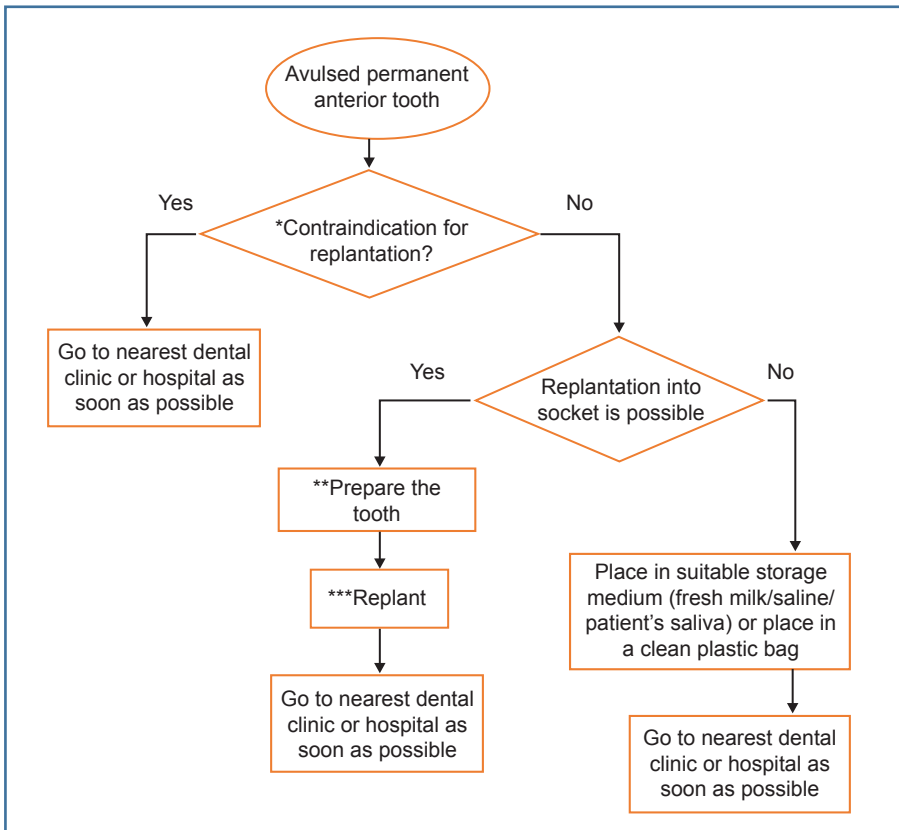
Dr Savithri N. Vengadasalam  
Head of Department  
Dental Public Health  
Faculty of Dentistry  
MAHSA University  
Jalan SP 2, Bandar Saujana Putra,  
42610 Jenjarom  
Selangor, Malaysia

Dr Susan Parekh  
Consultant in Paediatric Dentistry  
Department of Pediatric Dentistry  
UCL Eastman Dental Institute  
256 Grays Inn Road  
WC1X 8LD London  
United Kingdom

Madam Raja Intan Alfarisha Raja Alias  
Parent / Public  
Penasatria Sdn Bhd  
No 10-G-13, Ground Floor, Block 10,  
Desa Cempaka, 71800 Nilai  
Negeri Sembilan. Malaysia

Dr Nik Roslin Suraini Nik Sulaiman  
Private Dental Practitioner  
Klinik Pergigian Fauziah  
316G, Lorong Selangor  
Taman Melawati  
53100 Kuala Lumpur  
Malaysia

## ALGORITHM FOR MANAGEMENT OF AVULSED PERMANENT ANTERIOR TOOTH AT THE SITE OF INCIDENT



### \*Contraindication for replantation

Do not replant if the person suffers

- Other concomitant injury to the surrounding areas, the head or other part of the body
- Medical problem

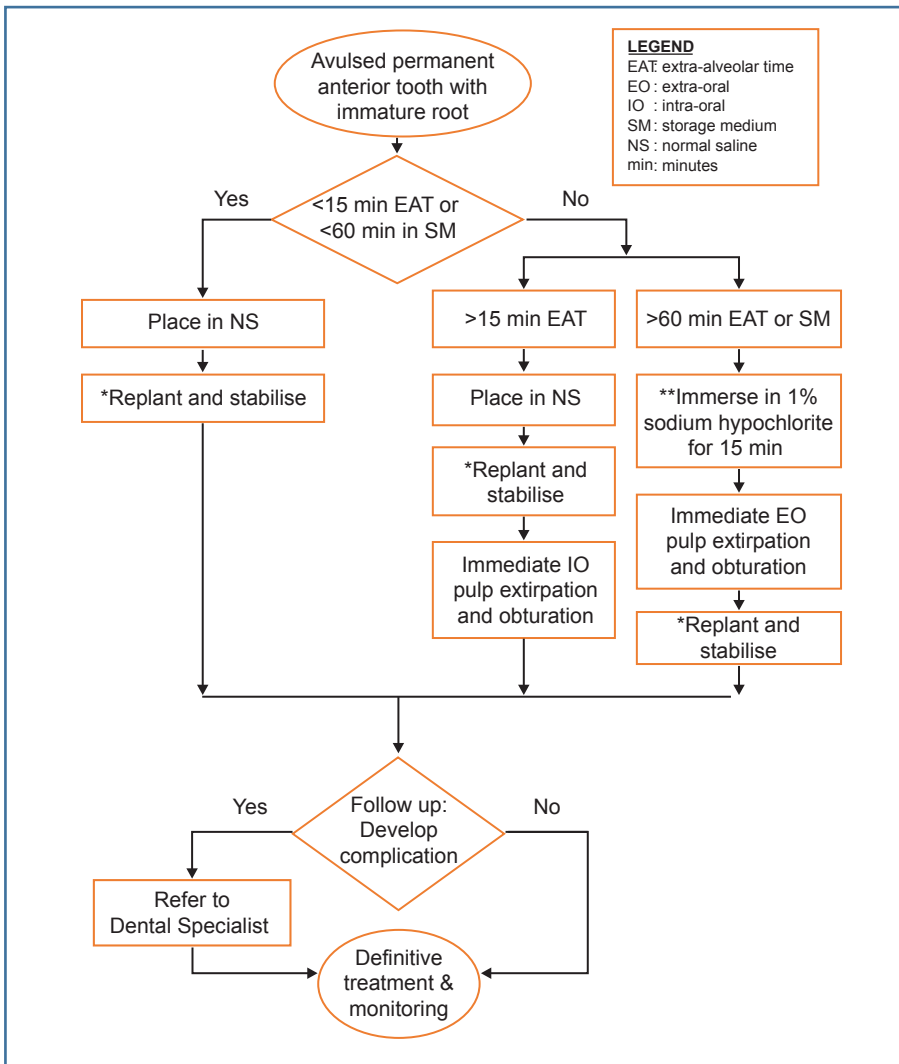
### \*\*Preparing the tooth for replantation

- Pick tooth by its crown. Do not hold or touch the root
- Check if the root is clean
- Rinse very briefly with normal saline or tap water for 10 seconds if dirt is present.  
Do not scrub dirt that is present on the root

### \*\*\*During replantation:

- Place avulsed tooth into socket gently
- Bite on a clean cloth

## ALGORITHM FOR MANAGEMENT OF AVULSED PERMANENT ANTERIOR TOOTH (IMMATURE ROOT) AT THE DENTAL CLINIC

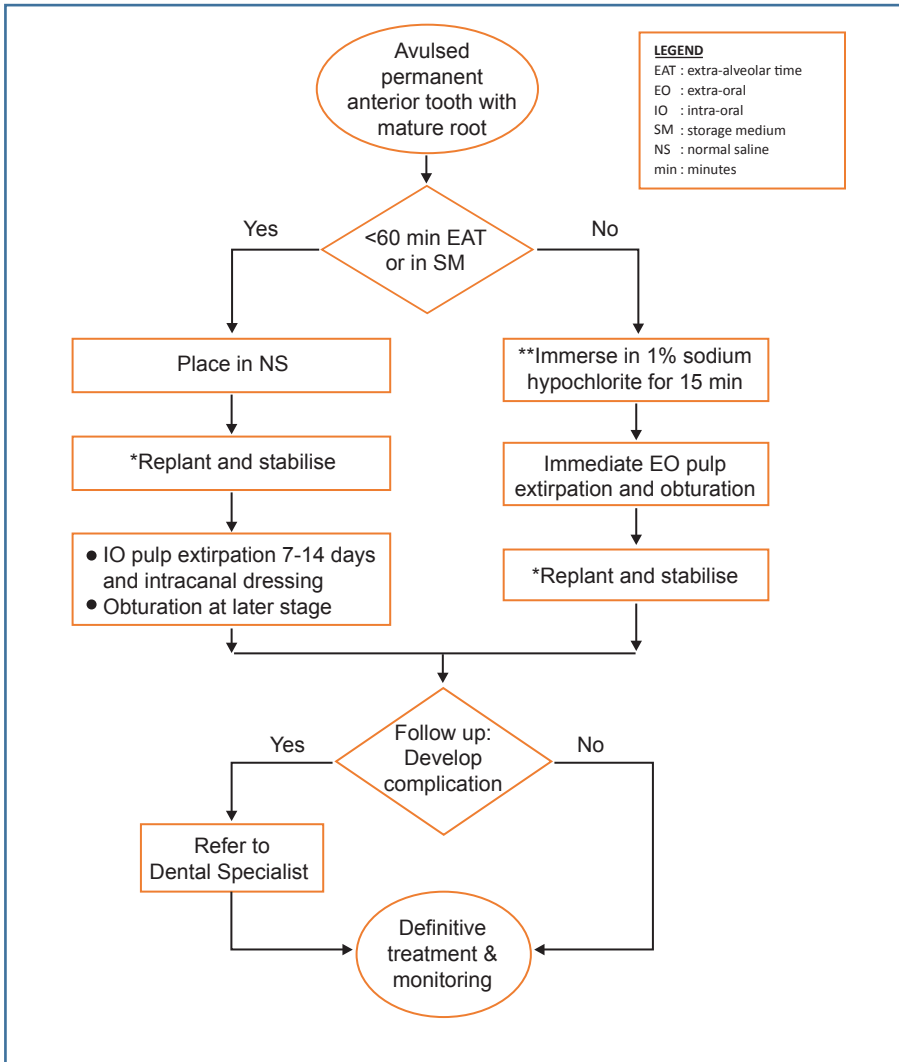


\*During replantation and stabilisation:

- Verify position with radiograph
- Splint for at least 7 days
- Prescribe antibiotic, analgesic and mouthwash

\*\*1% sodium hypochlorite can be prepared fresh with 1:5 dilution of 5% sodium hypochlorite (1 part bleach to 5 parts distilled water).

## ALGORITHM FOR MANAGEMENT OF AVULSED PERMANENT ANTERIOR TOOTH (MATURE ROOT) AT THE DENTAL CLINIC



\*During replantation and stabilisation:

- Verify position with radiograph
- Splint for at least 7 days
- Prescribe antibiotic, analgesic and mouthwash

\*\*1% sodium hypochlorite can be prepared fresh with 1:5 dilution of 5% sodium hypochlorite (1 part bleach to 5 parts distilled water).

## LIST OF KEY MESSAGES

### Key Message 1

- Intraoral radiographs are required for diagnosis and baseline record of avulsed permanent anterior teeth.
- Cone-beam computed tomography can be an advantage especially in the diagnosis and management of complex dental trauma.

### Key Message 2

- For an avulsed permanent anterior tooth, the best storage medium is the tooth socket itself.

### Key Message 3

- During follow-up, emphasis should be placed on the recognition of clinical and radiographical characteristics which represent the development of complications. This is to ensure measures can be instituted to reduce risk of failure and early loss of replanted avulsed permanent anterior teeth.



## LIST OF RECOMMENDATIONS

### Recommendation 1

- Avulsed permanent anterior tooth should be immediately replanted into its socket preferably within 15 minutes.
  - If immediate replantation is not possible, the avulsed permanent anterior tooth should be kept in an appropriate storage medium.

### Recommendation 2

- Replantation of avulsed permanent anterior tooth should not be carried out in patients who suffer severe concomitant injuries or are severely medically compromised.

### Recommendation 3

- Early pulp extirpation should be carried out for replanted mature avulsed permanent anterior tooth to minimise the possibility of inflammatory root resorption, which would cause early failure.
- For better outcome of replanted avulsed permanent anterior tooth with guarded prognosis, the pulp should be extirpated early within 7 to 14 days.

### Recommendation 4

- All cases of replanted avulsed permanent anterior teeth should be followed up for five years.

### Recommendation 5

- Autotransplantation may be considered in the management of ankylosed replanted avulsed permanent anterior teeth when donor tooth is available.

## 1. INTRODUCTION

Tooth avulsion (**Figure 1, 2 and 3**) is defined as the complete dislocation of a tooth from the alveolar bone and soft-tissue socket.<sup>1</sup> A sufficient force is required to disrupt the tooth from its periodontal ligament, as it is embraced in the alveolar socket.

The prevalence of tooth avulsion among adults aged 18 years and above ranged from 5% to 15%.<sup>2-6</sup> The number of individuals suffering from tooth avulsion increases with a decrease in age.<sup>7</sup> Adults aged between 18 to 30 years, have been shown to have the lowest number of tooth avulsion reported (15%), as compared to adolescents (17%) and children (68%).<sup>5</sup> In young children, the relatively resilient alveolar bone provides only minimal resistance to extrusive forces.

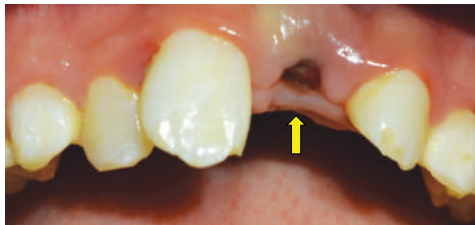The National Oral Health Survey of Schoolchildren in 2017 reported the prevalence of traumatised anterior teeth among children aged between 16 years and below to be 7.2%<sup>8</sup> which was lower than that reported in other countries.<sup>9-12</sup> 84.5% of the traumatised anterior teeth amongst 12 years old remained untreated.<sup>8</sup> A local retrospective study from 2001 to 2006 showed avulsion of permanent teeth occurred between the age of 10 and 13 years, with most cases involving permanent maxillary incisors.

The causative factors for traumatic dental injuries vary across age groups. Sports-related accidents are the main cause for trauma to anterior teeth in adolescents, while, the most prevalent cause for the late adolescents and young adults is car accidents.<sup>4</sup> In young children, the alleged identified causes for tooth avulsion were motor-vehicle accidents (57%), falls (40%) and hit by object (3%). More than 80% of the cases were referred to the Paediatric Dental Specialist from the Accident and Emergency Department of the local hospital.<sup>13</sup> Avulsion has also been reported as one of the common outcomes of domestic violence among women, children, adolescents and the elderly of both genders.<sup>14</sup>

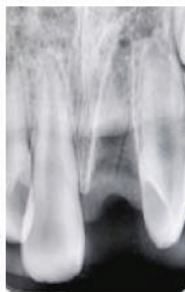
Traumatic dental injuries inclusive of tooth avulsion, showed higher prevalence in boys to girls.<sup>8, 11, 12, 15-17</sup> Boys tend to be more energetic and more inclined towards vigorous outdoor activities than girls.<sup>13, 18</sup> A significantly higher prevalence of traumatic dental injuries occurred in children with Class II Division 1 malocclusion, inadequate lip coverage and an overjet of more than 5 mm.<sup>12, 18-20</sup>

The management of avulsed permanent anterior teeth particularly during the emergency period can be distressing. An apparent lack of knowledge among public and healthcare professionals regarding the management of avulsed permanent anterior teeth results in delay in seeking treatment, inappropriate handling and treatment, affecting the prognosis of the avulsed teeth with unwarranted consequences.

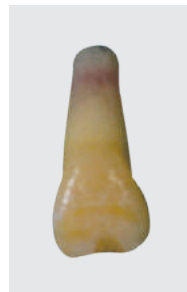Hence, it is of primary importance to develop effective interventional strategies, in order to avoid or alleviate the negative effects of tooth avulsion on quality of life, psychological and social problems, and high cost of treatment, both to patients and healthcare provider.



**Figure 1: Socket of an avulsed permanent anterior tooth.**  
Arrow showing the tooth socket.



**Figure 2: Radiographic image of an empty socket**



← Root with an immature apex  
← Crown part of a tooth

**Figure 3: An avulsed permanent anterior tooth**

## 2. EMERGENCY MANAGEMENT AT SITE OF INCIDENTS

### **(For patients / parents / teachers / paramedics and bystanders)**

Immediate replantation of an avulsed permanent anterior tooth is the main philosophy for treatment success and offers the greatest chance of tooth survival.<sup>21</sup>, level III Of utmost importance is the prevention of tooth being

dried, which causes loss of normal physiologic metabolism and morphology of the periodontal ligament cells for healing reattachment.<sup>22, level III</sup>

Time is a critical factor for the success of the management of avulsed permanent anterior teeth.<sup>23, 24, level III</sup> A systematic review showed that replantation of avulsed permanent teeth within 15 minutes gives a favourable long-term prognosis, with the least incidence of root resorption.<sup>25, level II-1</sup> Findings from other studies reveal significant improvements in periodontal healing for teeth stored in dry condition for less than 15 minutes. Therefore, every effort should be made to replant the tooth within the first 15 minutes.<sup>26-28, level II-2</sup> The aim is to replant a clean tooth into its socket with an undamaged root surface as gently as possible at the incident site, after which the patient should be brought to the clinic or hospital for treatment as quickly as possible.<sup>22, level III</sup>

The followings should be performed at the site of incident:

- i. Pick the tooth by its crown. Do not hold or touch the root.
- ii. Check to see if the root surface is clean.
- iii. Briefly rinse it with normal saline or tap water for 10 seconds if dirt is present. Do not scrub dirt that is present on the root.
- iv. Gently place the tooth into its socket without traumatising the tooth and the adjacent structures.
- v. Get the patient to bite on a clean cloth to keep the tooth in place.
- vi. Go to the nearest dental clinic as soon as possible.

If immediate replantation is not possible for any reason, the avulsed permanent anterior tooth should be stored in a suitable medium to be transported to the nearest dental clinic or hospital emergency service as soon as possible.<sup>29, 30</sup> Placing the avulsed permanent anterior tooth in a temporary physiologic storage solution has been reported to extend the viability of periodontal ligament cells before replantation.<sup>31-33, level III</sup> The most recommended storage medium is in the following order:

- Tooth socket
- Fresh milk
- Normal saline
- Patient's saliva

Other storage medium such as coconut water, propolis and green tea can also be considered. For more information, please refer to **Appendix 3**.

In the event that the above media are unavailable, the tooth should be placed in a clean plastic bag/container for transportation. The tooth may also be placed in the buccal sulcus (between the cheek and teeth) of the patient. However, this is not recommended for fear of accidental swallowing or aspiration, especially in a young child.

### **Recommendation 1**

- Avulsed permanent anterior tooth should be immediately replanted into its socket preferably within 15 minutes.
  - If immediate replantation is not possible, the avulsed permanent anterior tooth should be kept in an appropriate storage medium.

### **3. CONTRAINDICATIONS FOR REPLANTATION**

Replantation of an avulsed permanent anterior tooth is frequently the best treatment. Replantation is absolutely contraindicated in the following conditions:

- Where other injuries are more severe and warrant preferential emergency treatment and / or intensive care (such as severe head injury or poly-trauma)
- Patients with compromised medical history that would be put at risks by replantation of a tooth (such as immunodeficiency, congenital cardiac defects and bleeding dyscrasia). In this type of patient, it is prudent to discuss the treatment options with the medical physician in charge.

Replantation may not be appropriate in certain instances. However, decisions should be made on case by case basis. These include:

- The tooth has evidence of extensive caries or advanced periodontal disease
- The tooth has very short root (i.e. less than the crown length)
- The alveolar socket has major comminutions or fractures
- Uncooperative patient and / or non-compliant patient, parents or guardian

**Recommendation 2**

- Replantation of avulsed permanent anterior tooth should not be carried out in patients who suffer severe concomitant injuries or are severely medically compromised.

**4. CLINICAL MANAGEMENT****4.1. Informed Consent**

Informed consent should be obtained from patients (above 18 years old) / parents/ caretaker/ guardians in managing avulsed permanent anterior teeth.

**4.2. Pre-operative Assessment**

Pre-operative assessments must be thorough and well-documented to ensure proper management of avulsed permanent anterior teeth including related and accompanying hard and soft tissues injuries. The assessments should include the following:

- Medical history
- Trauma history
- Clinical examination
- Radiographic investigations
- Photographic records

For more information on patient's assessments, please refer to **Appendix 4**.

**4.3. Imaging**

Intraoral periapical radiograph should be taken for baseline records and diagnostic purposes. There is an increasing trend in the usage of cone-beam computed tomography (CBCT) in the management of dental trauma. However, there were no retrievable evidence on the use of CBCT for diagnosis and management of avulsed permanent anterior teeth. CBCT may be used in situations where three-dimensional imaging is required to facilitate diagnosis and treatment planning, especially in complex dental trauma.<sup>34, level III</sup>

**Key Message 1**

- Intraoral radiographs are required for diagnosis and baseline record of avulsed permanent anterior teeth.  
Cone-beam computed tomography can be an advantage especially in the diagnosis and management of complex dental trauma

**4.4. Replantation Technique**

The aim is to replant the avulsed permanent anterior tooth into its socket with minimal handling.

- i. Place the tooth in normal saline.
- ii. Administer local anaesthesia.
- iii. Gently irrigate the socket with normal saline.
- iv. For immediate or early replantation (<15 minutes extra-alveolar dry time or <60 minutes stored in recommended storage medium):
  - a. Handle the tooth by its crown. Do not touch the root.
  - b. Run normal saline over the tooth to remove any contamination.  
Gently dab with gauze soaked in normal saline if there is still residue of contamination.
  - c. It is advisable at this time to estimate the length of the tooth from tip of crown to apex. This is important as baseline for future endodontic treatment if needed.
  - d. Seat the tooth back gently into its socket using light finger pressure. Do not use excessive force.
  - e. Avoid scraping or curettage of the socket.
  - f. Avoid scraping off the root.
  - g. Stabilise the tooth by splinting
  - h. Take a periapical radiograph to verify the position of replanted avulsed permanent anterior tooth.
- v. For delayed replantation (>60 minutes extra-alveolar dry time or stored in recommended storage medium):
  - a. Remove old blood clot in the socket and induce fresh normal bleeding. Avoid scraping or excessive curettage of the socket.
  - b. Remove any visible contamination on the root surface with gauze.
  - c. Immerse the tooth into antiseptic agent 1% sodium hypochlorite for 15 minutes. 1% sodium hypochlorite can be prepared fresh with 1:5 dilution of 5% sodium hypochlorite (1 part bleach to 5 parts distilled water). Then, run normal saline over the tooth.

- d. Perform endodontic treatment as stated in Table 3.
- e. Seat the tooth back gently into its socket using light finger pressure. Do not use excessive force.
- f. Stabilise the tooth by splinting
- g. Take a periapical radiograph to verify the position of replanted avulsed permanent anterior tooth.

#### 4.5 Splinting Technique

The replanted avulsed permanent anterior tooth needs to be stabilised in position, by splinting for at least 7 days:

- i. Splint the avulsed permanent anterior tooth to the adjacent firm teeth
- ii. Different types of splinting methods can be utilised (**refer to section 5.6**)
- iii. Splinting should be extended to at least 4 weeks if there is a concomitant alveolar bone fracture.

#### 4.6 Post-operative care

The followings can be carried out after replantation and splinting:

- i. Prescribe
  - Systemic antibiotics (**refer to section 5.8**)
  - Oral analgesic (Paracetamol, Ibuprofen, Naproxen and Diclofenac are adequate to manage mild pain; however, moderate or severe pain requires combination with other agents, most commonly the opioid group)<sup>35, level III</sup>
  - 0.12% chlorhexidine gluconate mouthwash twice daily for 1 week
- ii. Home care advice includes:
  - Avoid biting on splinted teeth
  - Eat soft diet
  - Maintain good oral hygiene

## 5. PROGNOSTIC FACTORS

Knowledge on the factors that affect the prognosis of avulsed permanent anterior teeth is an essential element of the management process which dictates the decision making and actions of the healthcare provider.



The prognosis of replanted avulsed permanent anterior teeth depends on the vitality of pulp and viability of periodontal ligament cells. It is associated with various prognostic factors such as:- <sup>25, level II-1</sup>

- Extra-alveolar time (i.e. duration when tooth is out of its socket)
- Storage medium
- Tooth maturity (i.e. immature or mature apex)
- Root canal treatment (early or delayed)
- Contamination of root surface

However, the following factors may not affect the prognosis of avulsed permanent anterior teeth:

- Type and duration of splinting
- Root surface treatment
- Systemic antibiotics

### 5.1. Extra-alveolar Time

Extra-alveolar time is important in determining the viability of periodontal ligament cells. Total extra-alveolar time consists of extra-alveolar dry time, and time in storage medium. For better prognosis of periodontal healing, the followings should be obtained during history taking. <sup>25, level II-1</sup>

- Extra-alveolar dry time: <15 minutes
- Total extra-alveolar time (dry time and time in storage medium): <60 minutes

However, the best prognostic predictor is extra-alveolar dry time prior to storage or replantation of avulsed permanent anterior teeth.

### 5.2. Storage Medium

If for any reason immediate replantation is not possible, the avulsed permanent anterior tooth should be stored in a suitable medium, to be transported to the nearest dental clinic or hospital emergency service as soon as possible. <sup>29, 30, level III</sup> Storage in a suitable physiologic medium will ensure that the avulsed tooth is kept moist at all times. This will preserve and extend the viability of the periodontal ligament cells before replantation. <sup>31-33,</sup>

level III

The best storage medium is the tooth socket itself. Other considerations for storage medium are shown in **Table 1**.

**Table 1: Options of storage medium\***

STORAGE MEDIUM	PREPARATION
Milk	Pasteurized fresh or UHT milk, cold, low-fat, non-flavoured. <b>NOT</b> condensed or powdered milk.
Normal Saline	Physiological saline contains 0.9% sodium chloride
Saliva	Get the patient to spit into a clean container
Coconut water	Fresh tender coconut water
Propolis	10 – 50% concentration of natural propolis
Green tea	Commercial green tea extract (soaked in water for 5 min)
Egg	Egg white only

\*The temperature of the storage medium should be cold (not frozen) or within room temperature around  $26 \pm 2^{\circ}\text{C}$ . Do not use hot water or milk to store the tooth.

In the event that the above media are unavailable, the tooth should be placed in a clean plastic bag/ container for transportation. The efficacy and accessibility of storage medium is summarised in **Table 2**.<sup>31-33, level III</sup>

**Table 2: Storage medium according to their efficacy and accessibility**

EFFICACY ACCESSIBILITY	EXCELLENT	GOOD	POOR
	++	Milk	-
+	-	Coconut water, Egg	-
-	Propolis, Green tea	-	-

**++ easily available, + available, - less available**

Please refer to **Appendix 3** for further main characteristics, efficacy and accessibility of each storage medium for avulsed permanent anterior teeth.

### Key Message 2

- For an avulsed permanent anterior tooth, the best storage medium is the tooth socket itself.

### 5.3. Tooth Maturity

Tooth maturity is an important factor in determining the prognosis of avulsed permanent anterior teeth.

The absence of inflammatory root resorption is an indicator of periodontal healing. A meta-analysis on replanted avulsed teeth showed higher incidence of inflammatory (30%) and replacement (39%) root resorption in immature teeth compared to mature teeth (24% and 33% respectively).<sup>25, level II-1</sup>

With regards to pulp healing of immature avulsed permanent anterior tooth, shorter pulp length (less than  $\frac{3}{4}$  root form) shows higher chance of pulp revascularisation than longer pulp length. The pulp's width or diameter of apical foramen has no effect on the possibility of pulp revascularisation.<sup>36, level II-2</sup>

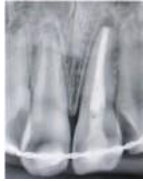For mature avulsed tooth where the apex is closed or nearly closed (<1mm), the possibility of pulp revascularisation is very minute.<sup>36, level II-2; 37-39, level III</sup>

### 5.4. Root Canal Treatment

Root canal treatment (**Figure 4**) in replanted avulsed permanent anterior tooth is routinely carried out to improve the prognosis.

In a meta-analysis on the influence of pulp extirpation of replanted avulsed permanent anterior teeth, there was significant difference in the development of inflammatory root resorption, within 14 days compared with after 14 days (OR=0.37, 95% CI 0.14 to 0.98). This means that delayed pulp extirpation will have higher incidence of inflammatory root resorption. On the contrary, there was no significant difference in terms of periodontal healing and replacement root resorption between both groups.<sup>40, level III</sup>

Early pulp extirpation at day 1 or day 2, especially in mature avulsed tooth, shows better periodontal ligament healing and less replacement root resorption compared with pulp extirpation done within day 3 - 14.<sup>26, level III</sup> However, early intervention of pulp extirpation must be balanced against the need to allow time for initial injury healing, and resolution of associated pain and swelling.



**Figure 4: Radiographic image of replanted avulsed permanent anterior tooth which was root canal treated extra-orally**

#### 5.4.1 Timing of pulp extirpation

Timing of pulp extirpation of a replanted avulsed permanent anterior tooth depends on extra-alveolar time and tooth maturity. These factors will determine the prognosis of the tooth whether it is good, guarded or poor (**Table 3**). Timing of endodontic management of a replanted avulsed permanent anterior tooth based on clinical presentations of different types of tooth maturity is shown in **Table 3**.

**Table 3: Tooth maturity and endodontic management**

	Tooth maturity				
	Immature root			Mature root	
Clinical presentation	<ul style="list-style-type: none"> <li>● &lt;15 min extra-alveolar dry time</li> <li>● &lt;60 min in storage medium</li> </ul>	<ul style="list-style-type: none"> <li>● &gt;15 min extra-alveolar dry time</li> </ul>	<ul style="list-style-type: none"> <li>● &gt;60 min extra-alveolar dry time or in storage medium</li> </ul>	<ul style="list-style-type: none"> <li>● &lt;60 min extra-alveolar dry time or in storage medium</li> </ul>	<ul style="list-style-type: none"> <li>● &gt;60 min extra-alveolar dry time or in storage medium</li> </ul>
Prognosis	Good	Guarded*	Poor	Guarded*	Poor

	Tooth maturity				
	Immature root			Mature root	
Endodontic management	<ul style="list-style-type: none"> <li>● Monitor</li> <li>● Pulp extirpation once sign and symptom present</li> </ul>	Early pulp extirpation intra-orally between 7 to 14 days	Extra-oral complete root canal treatment before replantation	Early pulp extirpation intra-orally between 7 to 14 days	Extra-oral complete root canal treatment before replantation

Guarded prognosis\*: the outcome is uncertain

An immature avulsed permanent anterior tooth which is replanted within 15 minutes or replanted within 60 minutes (stored in storage medium) would have good prognosis (**refer to section 5.1**). Therefore, root canal treatment can be delayed and the replanted tooth should be monitored regularly (**refer to section 6**) in order to determine if revascularisation would occur, or until there are definite signs of pulp necrosis.

Pulp extirpation should be performed early, preferably during extra-alveolar period prior to replantation of an avulsed permanent anterior tooth that has been stored dry, or in unsuitable storage medium for more than 60 minutes. Extra-alveolar root canal treatment showed no significant difference compared to intra-oral root canal treatment, in terms of treatment outcome of replanted avulsed permanent anterior teeth for longer than 60 minutes extra-alveolar dry time.<sup>41, level I</sup> Added advantages of extra-alveolar root canal treatment are ease of technique, and completed pulp extirpation and obturation in one sitting, which reduces the number of review visits and the need for patient co-operation.

For mature teeth where revascularisation is unlikely, early root canal treatment is recommended<sup>37-39, level III</sup> as a preventive approach to reduce the possibility of inflammatory resorption developing.<sup>37, level III</sup>

### Recommendation 3

- Early pulp extirpation should be carried out for replanted mature avulsed permanent anterior tooth to minimise the possibility of inflammatory root resorption, which would cause early failure
- For better outcome of replanted avulsed permanent anterior tooth with guarded prognosis, the pulp should be extirpated early within 7 to 14 days.

#### 5.4.2. Intracanal medications

Intracanal dressings in root canal treatment are used to inhibit or control the inflammatory resorption.<sup>42, level III</sup> The most widely used intra-canal medicament is non-setting calcium hydroxide.<sup>43, level III</sup> The main disadvantage of long-term use of calcium hydroxide is significant reduction in the strength of the teeth, causing an increase in fracture risk.<sup>44 level III</sup>

A water-soluble paste containing 1% triamcinolone and 3% demeclocycline has been advocated as intra-canal medicament for replanted avulsed teeth<sup>27, level II-2; 37, level III</sup> and became as a favoured material as calcium hydroxide.

A multi-centre randomised controlled trial comparing these two intra-canal medicaments (calcium hydroxide versus a water-soluble paste containing 1% triamcinolone and 3% demeclocycline), found no significant difference in the periodontal healing of replanted avulsed teeth.<sup>45, level I</sup>

#### 5.4.3. Obturation materials

Gutta-percha has been widely used as a root canal filling material. Gutta-percha must be used with root canal sealers to encourage adequate root canal seal.

Mineral Trioxide Aggregate and bioactive calcium silicate-based materials have been introduced recently as root canal filling, or apical plug for open apices and has been shown to result in favourable outcomes. Other advantages of these materials include reduced number of treatment visits, and reduced chances of fracture in the long term. The possible drawbacks of Mineral Trioxide Aggregate include crown discolouration, systemic effects and difficulty in removing the material during retreatment when used as a root filling material or apical plug.<sup>46, level III</sup>

#### 5.5. Contamination of Root Surface

The degree of contamination of the root surface of avulsed permanent anterior tooth is a risk factor for root resorption.<sup>47-49, level III</sup> The presence of foreign materials and bacteria will aggravate inflammatory response. Contamination on the root surface where viable periodontal ligament cells are present, should be carefully removed by washing with saline or damp gauze.

In delayed replantation, necrotic periodontal ligament cells and bacteria on the root surface should be removed. In an experimental study on necrotic periodontal ligament cells from delayed replanted teeth, the use of an antiseptic agent 1% sodium hypochlorite (NaOCl) for 15 minutes or 5.25%

NaOCl for five minutes was effective at removing the necrotic cells with minimal influence on cementum integrity. The usage of 1% NaOCl for 15 minutes was proven to be less damaging to the cementum.<sup>50, level III</sup>

### 5.6. Type and Duration of Splinting

The replanted avulsed permanent anterior tooth needs to be stabilised in position by a splint, to prevent further displacement and injury to the pulp and periodontal ligament during the healing phase. Available splints used for management of avulsed permanent anterior teeth are:

- Composite-wire splint (**Figure 5 and 6**)
- Direct composite splint
- Titanium trauma splint
- Button-bracket splint
- Fibre reinforced meshed splint

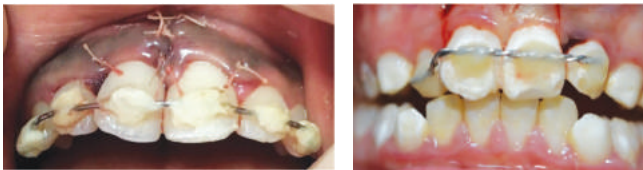

Figure 5 and 6: Examples of composite-wire splint

A systematic review showed that the periodontal healing outcome of traumatised teeth, including tooth avulsion, was not determined by type of splint.<sup>51, level II-2</sup> Therefore, the choice of splinting material depends on its availability in local settings.

The prevalence of root resorption was slightly lower in splinting period of 4 – 10 days compared with 11 – 19 days and > 20 days, although it was non-significant. There was no significant difference observed in periodontal healing > 40 days of splinting, compared with a shorter period.<sup>52, level II-2</sup>

For local setting, the splinting period of at least 7 days is fairly reasonable to allow healing, as well as to comply with the follow-up intervals. The removal of splint depends on the clinical presentations (e.g. reduced mobility to grade 1 or physiological mobility) during the follow-up review.

### 5.7. Root Surface Treatment

The use of enamel matrix protein derivatives in avulsed permanent teeth has no beneficial effect on the prognosis.<sup>25, level II-1</sup> Moreover, there is insufficient retrievable evidence to show the effectiveness and safety of other root surface treatment on the periodontal regeneration. Therefore, the CPG development group is unable to suggest any forms of root surface treatment (e.g. fluoride, enamel matrix protein derivatives, citric acid and antibiotics) in the management of avulsed permanent anterior teeth.

### 5.8. Systemic Antibiotics

Systemic antibiotics is commonly prescribed to treat and prevent dental infections. Infections in replanted avulsed permanent anterior teeth may be caused by bacterial contamination of the pulp and the periodontal ligament, from the environment and exposure to saliva during replantation. These infections may eventually lead to inflammatory root resorption.<sup>53, level III</sup>

A meta-analysis on systemic antibiotic prescription for replanted avulsed teeth showed inconclusive evidence of acceptable healing. However, systemic antibiotics may be indicated in the following conditions: <sup>53, level III</sup>

- Gross contamination of the tooth and soft tissue
- Severe injury including injuries to other body sites
- Patients with medical conditions that are prone to infection
- Inability to keep injury site free from contamination

Based on National Antibiotic Guidelines 2<sup>nd</sup> Edition in 2017, penicillin-based antibiotics (e.g. penicillin V or ampicillin or amoxicillin) can be prescribed immediately if indicated.<sup>54, level III</sup>

## 6. FOLLOW-UP AND MONITORING

Follow-up and monitoring of replanted avulsed permanent anterior tooth are an important aspect of its management. Once the avulsed tooth is replanted and stabilised, it is crucial that the tooth is followed up according to planned intervals. During the follow-up, the pulpal and periodontal condition are assessed, and possible outcomes of healing and complications are carefully evaluated. The clinical and radiographic parameters to be assessed and recorded during review appointments are shown in **Appendix 5**.



Pulpal healing following replantation can be determined clinically by a positive sensibility response, and radiographically by obliteration of the root canal or continuation of root development during the follow-up. Periodontal healing is observed by the absence of root resorption as well as evidence of either complete, partial or arrested root growth formation for immature apex.<sup>55, level II-3</sup>

### Key Message 3

- During follow-up, emphasis should be placed on the recognition of clinical and radiographical characteristics which represent the development of complications. This is to ensure measures can be instituted to reduce risk of failure and early loss of replanted avulsed permanent anterior teeth.

Refer to **Appendix 6** for possible complications, expected timing of occurrence and, clinical and radiographic findings.

### 6.1. Follow-up Intervals

Patients with replanted avulsed permanent anterior tooth should be reviewed at the following intervals post-replantation:<sup>56, 57, level III</sup>

- 1 week
- 2 weeks
- 1 month
- 3 months
- 6 months
- every 6 months until 2 years
- yearly thereafter until 5 years

At every follow-up after the first month, sensibility test and radiographic examination should be performed.

### Recommendations 4

All cases of replanted avulsed permanent anterior teeth should be followed up for five years.\*

*\*Refer to the preceding text on follow-up intervals.*

## 6.2. Complications of Replanted Avulsed Permanent Anterior Tooth

Complications of replanted avulsed permanent anterior tooth is a common occurrence. The followings are the possible complications of replanted avulsed permanent anterior tooth with clinical importance:

- pulpal necrosis
- inflammatory root resorption
- replacement root resorption or ankylosis
- tooth loss

### 6.2.1. Pulpal Necrosis

Pulpal necrosis is the most common pulp complication.<sup>58, level III</sup> Once vessels are severed due to avulsion, infarction and coagulation necrosis of pulp occurs. The pulp often becomes contaminated by microorganisms from the extra-oral and intra-oral environment. Continual bacterial contamination of the pulp and root surface leads to infection, which could arrest pulp revascularisation and cause total pulp necrosis.<sup>36, level II-2, 37, level III</sup>

Pulpal necrosis can be detected as early as two weeks following replantation, and can occur at any time during the early two-year period of replantation (refer **Appendix 6**).<sup>56, level III</sup>

### 6.2.2. Inflammatory Root Resorption

The development of inflammatory root resorption is directly related to the mechanical damage of the periodontium at the time of trauma.<sup>36, level II-2, 37, level III</sup> Loss of cementum results in dentinal tubule exposure to the surrounding periodontal ligament and bone. In addition, untreated pulpal necrosis due to contamination of bacteria within the root canal and dentinal tubules, contributes to and aggravates the inflammatory root resorption process. Furthermore, inflammatory root resorption could cause dentine exposure through which toxins from bacteria present in the tubules and/or the infected root canal can be transmitted to the periodontal ligament.<sup>37, level III</sup>

Inflammatory root resorption occurs in 23% (range of 0% to 64%)<sup>25, level II-1</sup> of replanted avulsed permanent anterior teeth and can usually be diagnosed at 8 months (between 5 and 12 months) post-replantation.<sup>56, level III</sup> Immature teeth demonstrated slightly higher prevalence to mature teeth of developing inflammatory root resorption, despite having the potential for pulpal revascularisation (6.2%-69.2% for immature teeth and 2.8%-64.3% for mature teeth).<sup>25, level II-1</sup>

### 6.2.3. Replacement Root Resorption or Ankylosis

Replacement root resorption is the predominant type of root resorption. It occurs in 51% (range of 13% to 100%) of replanted avulsed permanent anterior teeth.<sup>25, level II-1</sup> Clinically, it is common to detect replacement root resorption at 14 months (range between 6 – 24 months).<sup>56, level III</sup>

Replacement root resorption is a serious complication following the death of viable periodontal ligament cells. The damaged periodontal ligament is being replaced by bone tissues causing fusion of tooth and bone or ankylosis. Continued replacement of the cementum and dentin eventually result in total replacement of tooth root with alveolar bone. This is of particular concern in younger patients, who have not reached their full growth potential, where ankylosis can have greater effects than in adults.

### 6.2.4. Tooth Loss

Failure of replanted avulsed permanent anterior tooth will lead to its loss. Survival rate of replanted avulsed permanent anterior tooth ranges from 70 – 83%.<sup>36, level II, 26, 59, level III</sup>

## 7. MANAGEMENT OF COMPLICATIONS

Proper and timely management of complications of replanted avulsed permanent anterior tooth could help to reduce risks of its failure and early loss.<sup>37, level III</sup>

### 7.1. Pulp Necrosis and Inflammatory Root Resorption

Early pulp extirpation of replanted mature avulsed permanent anterior tooth should be performed to prevent complication of pulpal necrosis.<sup>26, level III</sup> Failure to extirpate the necrotic pulp tissue will lead to uncontrolled infection and the development of inflammatory resorption,<sup>26, level III</sup> subsequently resulted in tooth loss.<sup>40, level II-2</sup>

Replanted immature avulsed permanent anterior tooth has the potential for pulp revascularisation. It should be carefully monitored during follow-ups (**refer to section 1.1**). Immediate root canal treatment is indicated if there are clinical and radiographic signs of inflammatory root resorption.<sup>37, level III</sup> After completion of root canal treatment, the replanted tooth should be reviewed for any signs or symptoms of further infections.

## 7.2. Replacement Root Resorption or Ankylosis

There is insufficient high-quality evidence regarding the management of replacement root resorption or ankylosed replanted avulsed permanent anterior tooth which poses a great challenge for clinical practice. Its management is complex and requires short- and long-term treatment planning with inter-disciplinary involvements.

Tooth ankylosis in growing children often leads to failure of eruption resulting in infra-occlusion. It disrupts local alveolar growth development and results in space loss, tilting of adjacent teeth and poor aesthetic. The progression of replacement root resorption in young children can be rapid, especially when diagnosed before the age of 10. <sup>60, level II-2</sup>

On the contrary, tooth ankylosis in older patients may be considered an acceptable outcome. This age group has achieved skeletal maturity and the replacement resorption progress is slow. Minor infra-occlusion may not cause major aesthetic concerns. The ankylosed tooth can survive for a number of years, before total bony replacement of root occurs. Eventually, the crown may be lost spontaneously or by surgical intervention. <sup>60, level II-2</sup>

In the management of ankylosed replanted avulsed permanent anterior teeth, clinicians should base the treatment planning on their experience and skill, patients' preferences and perspectives. The interventions of ankylosed replanted avulsed permanent anterior teeth are as follows:

- Tooth autotransplantation<sup>61, level II-2; 62, level III</sup>
- Decoronation<sup>63, level II-2; 64, 65, level III</sup>
- Surgical luxation or intentional luxation<sup>66, level III</sup>
- Orthodontic treatment with distraction osteogenesis<sup>67, level III</sup>
- Surgical osteotomy and distraction osteogenesis<sup>68, level III</sup>
- Minor modifications of crown with composite build-up<sup>69, level II-2</sup>

Amongst all the above-mentioned techniques, the most commonly performed procedures are tooth autotransplantation and decoronation. <sup>61, level II-2; 62-65, level III; 70-73, level II-2</sup>

Whereas, other techniques are novel and may not be replicated due to the specific presentation of the cases. <sup>66-68, level III</sup>

### 7.2.1. Tooth autotransplantation

Tooth autotransplantation in healthy growing children and adolescents may be considered for the replacement of ankylosed replanted avulsed permanent anterior tooth, when appropriate donor is available. Premolar is the most common donor tooth in autotransplantation. Orthodontic consultation is required in the treatment planning as part of a multidisciplinary team approach, before performing premolar autotransplantation.

A meta-analysis of autotransplantation of teeth with incomplete root formation reported a 10-year survival rate of 96.3% (CI 89.8 – 98.7%), whilst the weighted estimated success rate per year was 96.6% (CI 97.8 – 94.8%). The rate of complications such as ankylosis, root resorption, and pulp necrosis was found to be low (<5%).<sup>61, level II-2</sup>

A systematic review of premolar autotransplantation to anterior maxilla showed survival rate of 96.7% at 9 months - 22 years of follow-up. However, the quality of primary papers included in this study were of low to moderate level.<sup>62, level III</sup>

A successful tooth autotransplantation allows continuous tooth eruption, preservation of alveolar bone volume, tooth movement by orthodontic forces and normal proprioception in contrast to osseointegrated dental implant.<sup>72, 73, level II-2</sup>

Hence, a successful tooth autotransplantation represents a good alternative to orthodontic space closure or prosthetic replacement.

#### Recommendation 5

- Autotransplantation may be considered in the management of ankylosed replanted avulsed permanent anterior teeth when donor tooth is available.

### 7.2.2. Decoronation

The purpose of decoronation is to preserve alveolar bone volume and to prevent further infra-occlusion in growing children.<sup>63, level III</sup> Tooth extraction is known to cause up to 50% resorption of the alveolar ridge width within 3 months.<sup>74, level III</sup> Though decoronation may offer the most benefits when it is performed at the age of rapid growth whereby it may preserve alveolar bone height,<sup>63, level III</sup> contradicting evidence were also retrieved.<sup>65, level III</sup>

Decoronation must be weighed against the need for temporary prosthetic replacement in young growing patients, when permanent prosthesis such as implant is contraindicated.

### 7.3. Tooth Loss (Interim and Long-term Treatment Options)

Failure to replant or failure following replantation of avulsed permanent tooth will lead to premature loss of permanent maxillary anterior tooth.

Alveolar ridge preservation (ARP) procedures following tooth loss have been introduced to minimise alveolar ridge atrophy to facilitate future implant placement. Various techniques or materials used for ARP can be categorised into three:- <sup>75, level II-2</sup>

- Bone grafts/ substitutes (i.e. autologous bone and platelet-rich plasma or PRP)
- Guided Bone Regeneration (GBR) (i.e. collagen membrane)
- Biological active materials (i.e. bone morphogenic protein).

In a systematic review on ARP, the reduction in ridge width and height following different ARP techniques may be less than that which occurs following natural socket healing. However, ARP does not totally eliminate post-extraction alveolar ridge resorption or predictably promote new bone formation. <sup>75, level II-2</sup> Clinicians may consider ARP in situations requiring that implant placement is significantly delayed after tooth extraction, such as, due to the young age of the patient. <sup>76, level III</sup>

Long-term treatment options can be considered for the treatment of lost tooth. The treatment options are as follows:

- Space maintenance using:
  - removable or fixed denture prosthesis (FDPs)
  - tooth autotransplantation (e.g. autotransplantation of developing premolar)
  - implant prosthesis
- Orthodontic space closure
- Orthodontic space closure in combination with prosthesis/ tooth autotransplantation/ implant (for cases involving loss of multiple maxillary anterior teeth)

Tooth avulsion of permanent anterior tooth occurs most commonly in children and adolescents, during which facial growth is not completed. Therefore, patients may have to wear non-invasive interim restorations during this growth period prior to more definitive treatment. The interim restorations available are:

- removable retainer
- metal resin-bonded FDPs
- ceramic resin-bonded FDPs
- fibre-reinforced composite resin-bonded restorations

Survival rates for both resin-bonded FDPs and composite resin-bonded restorations are 73% at 4.5 years.<sup>77, level III</sup> The success rate of tooth autotransplantation when using premolar to replace maxillary incisors can be very high (i.e. 100% at 4.8 years).<sup>71, level II-2</sup>

As for implants, it should not be placed until the skeletal growth is completed. Thus, this is a major disadvantage of planning aesthetic treatment with implants as an option for the management of unsuccessful replanted avulsed permanent anterior tooth among children and adolescents. Therefore, patient's age should be considered in the treatment strategy for anterior permanent tooth loss due to avulsion or failed replanted avulsed permanent anterior tooth.

## 8. IMPLEMENTING THE GUIDELINES

It is important to standardise the management of avulsed permanent anterior teeth at all healthcare levels in Malaysia using an evidence-based CPG in order to manage it appropriately.

The outcomes of treatment are mostly dependent on the timely and appropriate management of the avulsed permanent anterior teeth. Recognition of the prognostic factors such as extra-alveolar time, appropriate storage media and root canal treatment by clinicians, the knowledge of what to do when a problem occurs, and the appropriate responses from the health professionals are major factors in the management of avulsed permanent anterior teeth. This professional awareness is influenced by factors such as maintaining current understanding of the nature of avulsed teeth, the appropriate management, continuing professional education and an understanding of parents' and patient's expectations.

Therefore, it is important for these guidelines to be disseminated to all healthcare professionals in primary and secondary healthcare facilities. This can further be facilitated through the development of appropriate training modules and quick references. These guidelines will also be beneficial to the public by making this CPG available in a structured, user-friendly manner on the internet.

Several factors may affect the implementation of the recommendations of the CPG

### **8.1. Facilitating and Limiting Factors**

Existing facilitators for application of the recommendations in the CPG include:

- a) wide dissemination of the CPG to healthcare professionals and teaching institutions via printed and electronic copies
- b) continuing professional education on the management of avulsed permanent anterior teeth for healthcare professionals
- c) adequate facilities at primary and secondary care level for diagnosing and treating avulsed permanent anterior teeth
- d) involvement of non-government organisations e.g. Malaysian Association of Paediatric Dentistry in Dental Trauma Talk and Workshop

Existing barriers for application of the recommendations of the CPG include:

- a) lack of understanding or limited knowledge on the management of avulsed permanent anterior teeth
- b) variation in skills and treatment practices
- c) constraints in equipment and facilities

### **8.2. Potential Resource Implications**

To implement the CPG, there must be strong commitment to

- a) ensure widespread distribution of the CPG in hard and soft copy to healthcare professionals in primary and secondary healthcare facilities
- b) strengthen training of healthcare professionals to ensure knowledge and information is up to date.
- c) empower community with active involvement in trauma prevention and management related activities



### 8.3. Proposed Clinical Audit Indicators.

To assist in the implementation of the CPG, the following are proposed as clinical audit indicators for quality management of avulsed permanent anterior teeth:

Retention rate of replanted avulsed permanent anterior teeth over 2 years	=	$\frac{\text{Number of replanted avulsed permanent anterior teeth retained 2 years post operatively}}{\text{Total number of replanted avulsed permanent anterior teeth over 2 years}}$	X	100%
---	---	--	---	------

## REFERENCES

1. Howe AS. Craniomaxillofacial Injuries. In: Seidenberg PH, Beutler AI, editors. *The Sports Medicine Resource Manual*. 1 ed. Philadelphia; Edinburgh: Elsevier Saunders; 2008. p. 253-71.
2. Bergman L, Milardovic Ortolan S, Zarkovic D, Viskic J, Jokic D, Mehulic K. Prevalence of dental trauma and use of mouthguards in professional handball players. *Dent Traumatol*. 2017; 33(3): 199-204.
3. Ugolini A, Parodi GB, Casali C, Silvestrini-Biavati A, Giacinti F. Work-related traumatic dental injuries: Prevalence, characteristics and risk factors. *Dent Traumatol*. 2018; 34(1): 36-40.
4. Enabulele JE, Oginni AO, Sede MA, Oginni FO. Pattern of traumatised anterior teeth among adult Nigerians and complications from late presentation. *BMC Res Notes*. 2016; 9(1): 70.
5. Rebouças PD, Macedo-Rodrigues LW, de Sousa Santiago AK, Gondim JO, Neto JJSM. Prevalence of permanent teeth avulsion in a Brazilian trauma center: A 12 years retrospective study. *Braz Dent Sci*. 2015; 18(3): 3-9.
6. Lauridsen E, Hermann NV, Gerds TA, Kreiborg S, Andreasen JO. Pattern of traumatic dental injuries in the permanent dentition among children, adolescents, and adults. *Dental Traumatology*. 2012; 28(5): 358-363.
7. Mesquita GC, Soares PBF, Moura CCG, Roscoe MG, Paiva SM, Soares CJ. A 12-year retrospective study of avulsion cases in a Public Brazilian Dental Trauma Service. *Braz Dent J*. 2017; 28(6): 749-756.
8. Oral Health Division Ministry of Health Malaysia. *National Oral Health Survey of Schoolchildren 2017 (NOHS 2017)*. Putrajaya: Ministry of Health Malaysia; 2017.
9. Cavalcanti AL, Bezerra PKM, De Alencar CRB, Moura C. Traumatic anterior dental injuries in 7-to 12-year-old Brazilian children. *Dent Traumatol*. 2009; 25(2): 198-202.
10. Adekoya-Sofowora CA, Adesina OA, Nasir WO, Oginni AO, Ugboko VI. Prevalence and causes of fractured permanent incisors in 12-year-old suburban Nigerian schoolchildren. *Dent Traumatol*. 2009; 25(3): 314-317.
11. Bratteberg M, Thelen DS, Klock KS, Bårdsen A. Traumatic dental injuries and experiences along the life course—a study among 16-yr-old pupils in western Norway. *Eur J Oral Sci*. 2019.

12. Khandelwal V, Nayak UA, Nayak PA, Ninawe N. Prevalence of traumatic injuries to the anterior teeth among 3-17-year-old school children of Indore and correlating it with Kuppuswamy SES, occlusal relationship and ascertaining percentage of those seeking the treatment. *Int J Adolesc Med Health*. 2018.
13. Mohd Ali A, H H. Clinical review on dental avulsion amongst children in Hospital Sultanah Bahiyah 2001-2006. 6th Conference of Pediatric Dentistry Association of Asia 2008.
14. Garbin CAS, e Queiroz G, Rovida TAS, Garbin AJI. Occurrence of traumatic dental injury in cases of domestic violence. *Brazilian dental journal*. 2012; 23(1): 72-76.
15. Damé-Teixeira N, Alves LS, Susin C, Maltz M. Traumatic dental injury among 12-year-old South Brazilian schoolchildren: Prevalence, severity, and risk indicators. *Dent Traumatol*. 2013; 29(1): 52-58.
16. Hasan AA, Qudeimat MA, Andersson L. Prevalence of traumatic dental injuries in preschool children in Kuwait—a screening study. *Dent Traumatol*. 2010; 26(4): 346-350.
17. Jagger RG, Abbasbhai A, Patel D, Jagger DC, Griffiths A. The prevalence of dental, facial and head injuries sustained by schoolboy rugby players. A pilot study. *Prim Dent Care*. 2010; 17(3): 143-146.
18. Zaleckiene V, Peciuliene V, Brukiene V, Drukteinis S. Traumatic dental injuries: Etiology, prevalence and possible outcomes. *Stomatologija*. 2014; 16(1): 7-14.
19. Ravishankar TL, Kumar MA, Ramesh N, Chaitra TR. Prevalence of traumatic dental injuries to permanent incisors among 12-year-old school children in Davangere, South India. *Chin J Dent Res*. 2010; 13(1): 57-60.
20. Patel MC, Sujan SG. The prevalence of traumatic dental injuries to permanent anterior teeth and its relation with predisposing risk factors among 8-13 years school children of Vadodara city: An epidemiological study. *J Indian Soc Pedod Prev Dent*. 2012; 30(2): 151.
21. Singletary EM, Zideman DA, De Buck EDJ, Chang W-T, Jensen JL, Swain JM, et al. Part 9: First aid: 2015 International consensus on first aid science with treatment recommendations. *Circulation*. 2015; 132(16\_suppl\_1): S269-S311.
22. Trope M. Avulsion of permanent teeth: Theory to practice. *Dent Traumatol*. 2011; 27(4): 281-294.

23. McIntyre JD, Lee JY, Trope M, Vann, Jr., William F. Permanent tooth replantation following avulsion: Using a decision tree to achieve the best outcome. *Pediatr Dent.* 2009; 31(2): 137-144.
24. Petrovic B, Marković D, Peric T, Blagojevic D. Factors related to treatment and outcomes of avulsed teeth. *Dent Traumatol.* 2010; 26(1): 52-59.
25. Souza BDM, Dutra KL, Kuntze MM, Bortoluzzi EA, Flores-Mir C, Reyes-Carmona J, et al. Incidence of root resorption after the replantation of avulsed teeth: A meta-analysis. *J Endod.* 2018; 44(8): 1216-1227.
26. Werder P, von Arx T, Chappuis V. Treatment outcome of 42 replanted permanent incisors with a median follow-up of 2.8 years. *Schweiz Monatsschr Zahnmed.* 2011; 121(4): 312-20.
27. Chappuis V, Von Arx T. Replantation of 45 avulsed permanent teeth: A 1-year follow-up study. *Dent Traumatol.* 2005; 21(5): 289-296.
28. Andersson L, Bodin I. Avulsed human teeth replanted within 15 minutes - a long-term clinical follow-up study. *Dent Traumatol.* 1990; 6(1): 37-42.
29. Moule A, Cohenca N. Emergency assessment and treatment planning for traumatic dental injuries. *Aust Dent J.* 2016; 61 Suppl 1: 21-38.
30. Andreasen JO, Lauridsen E, Gerds TA, Ahrensburg SS. Dental Trauma Guide: A source of evidence-based treatment guidelines for dental trauma. *Dent Traumatol.* 2012; 28(5): 345-350.
31. Adnan S, Lone MM, Khan FR, Hussain SM, Nagi SE. Which is the most recommended medium for the storage and transport of avulsed teeth? A systematic review. *Dent Traumatol.* 2018; 34(2): 59-70.
32. Poi WR, Sonoda CK, Martins CM, Melo ME, Pellizzer EP, Mendonça MRd, et al. Storage media for avulsed teeth: A literature review. *Braz Dent J.* 2013; 24(5): 437-445.
33. Udoye CI, Jafarzadeh H, Abbott PV. Transport media for avulsed teeth: A review. *Aust Endod J.* 2012; 38(3): 129-136.
34. Kullman L, Al Sane M. Guidelines for dental radiography immediately after a dento-alveolar trauma, a systematic literature review. *Dent Traumatol.* 2012; 28(3): 193-199.
35. Verghese ST, Hannallah RS. Acute pain management in children. *J Pain Res.* 2010; 3: 105-123.

36. Andreasen JO, Borum MK, Jacobsen HL, Andreasen FM. Replantation of 400 avulsed permanent incisors. 2. Factors related to pulpal healing. *Dent Traumatol.* 1995; 11(2): 59-68.
37. Abbott PV. Prevention and management of external inflammatory resorption following trauma to teeth. *Aust Dent J.* 2016; 61: 82-94.
38. Sigurdsson A. The treatment of traumatic dental injuries 2014. Available from: [www.aae.org/clinical-resources/trauma-resources.aspx](http://www.aae.org/clinical-resources/trauma-resources.aspx).
39. Andersson JO, Andreasen FM. Avulsion. In: Andersson JO, Andreasen FM, Andersson L, editors. *Textbook and Color Atlas of Traumatic Injuries to Teeth.* 4 ed. Oxford: Blackwell Publishing; 2007. p. 444-488.
40. Hinckfuss SE, Messer LB. An evidence-based assessment of the clinical guidelines for replanted avulsed teeth. Part I: Timing of pulp extirpation. *Dent Traumatol.* 2009; 25(1): 32-42.
41. Day PF, Duggal M, Nazzal H. Interventions for treating traumatised permanent front teeth: Avulsed (knocked out) and replanted. *Cochrane Database Syst Rev.* 2019; (2).
42. Mohammadi Z, Dummer PMH. Properties and applications of calcium hydroxide in endodontics and dental traumatology. *Int Endod J.* 2011; 44(8): 697-730.
43. Madarati AA, Zafar MS, Sammani AMN, Mandorah AO, Bani-Younes HA. Preference and usage of intracanal medications during endodontic treatment. *Saudi Med J.* 2017; 38(7): 755.
44. Batur YB, Erdemir U, Sancakli HS. The long-term effect of calcium hydroxide application on dentin fracture strength of endodontically treated teeth. *Dent Traumatol.* 2013; 29(6): 461-464.
45. Day PF, Gregg TA, Ashley P, Welbury RR, Cole BO, High AS, et al. Periodontal healing following avulsion and replantation of teeth: A multi-centre randomized controlled trial to compare two root canal medicaments. *Dent Traumatol.* 2012; 28(1): 55-64.
46. Torabinejad M, Parirokh M, Dummer PMH. Mineral trioxide aggregate and other bioactive endodontic cements: An updated overview—part II: Other clinical applications and complications. *Int Endod J.* 2018; 51(3): 284-317.
47. Donaldson M, Kinirons MJ. Factors affecting the time of onset of resorption in avulsed and replanted incisor teeth in children. *Dent Traumatol.* 2001; 17(5): 201-205.

48. Kinirons MJ, Gregg TA, Welbury RR, Cole BOI. Dental trauma: Variations in the presenting and treatment features in reimplanted permanent incisors in children and their effect on the prevalence of root resorption. *Br Dent J.* 2000; 189(5): 263.
49. Andreasen JO, Borum MK, Jacobsen HL, Andreasen FM. Replantation of 400 avulsed permanent incisors. 1. Diagnosis of healing complications. *Dent Traumatol.* 1995; 11(2): 51-58.
50. Bai J, Qin M, Zhao YM, Huang MW, Ji AP. Chemical removal of necrotic periodontal ligament on delayed replanted teeth by sodium hypochlorite: morphological analysis and microhardness indentation test of cementum. *Int Endod J.* 2016; 49(4): 393-401.
51. Kahler B, Heithersay GS. An evidence-based appraisal of splinting luxated, avulsed and root-fractured teeth. *Dent Traumatol.* 2008; 24(1): 2-10.
52. Hinckfuss SE, Messer LB. Splinting duration and periodontal outcomes for replanted avulsed teeth: A systematic review. *Dent Traumatol.* 2009; 25(2): 150-157.
53. Hinckfuss SE, Messer LB. An evidence-based assessment of the clinical guidelines for replanted avulsed teeth. Part II: Prescription of systemic antibiotics. *Dent Traumatol.* 2009; 25(2): 158-164.
54. Ministry of Health Malaysia. National Antibiotic Guidelines. 2nd ed. Putrajaya: Ministry of Health Malaysia; 2017.
55. Andreasen JO, Borum MK, Jacobsen HL, Andreasen FM. Replantation of 400 avulsed permanent incisors. 4. Factors related to periodontal ligament healing. *Dent Traumatol.* 1995; 11(2): 76-89.
56. Lin S, Pilosof N, Karawani M, Wigler R, Kaufman AY, Teich ST. Occurrence and timing of complications following traumatic dental injuries: A retrospective study in a dental trauma department. *J Clin Exp Dent.* 2016; 8(4): e429.
57. Andersson L, Andreasen JO, Day P, Heithersay G, Trope M, Diangelis AJ, et al. International Association of Dental Traumatology guidelines for the management of traumatic dental injuries: 2. Avulsion of permanent teeth. *Dent Traumatol.* 2012; 28(2): 88-96.
58. Rocha Lima TF, Nagata JY, de Souza-Filho FJ, de Jesus Soares A. Post-traumatic complications of severe luxations and replanted teeth. *J Contemp Dent Pract.* 2015; 16(1): 13-19.

59. Karayilmaz H, Kirzioglu Z, Gungor OE. Aetiology, treatment patterns and long-term outcomes of tooth avulsion in children and adolescents. *Pak J Med Sci.* 2013; 29(2): 464-468.
60. Malmgren B, Malmgren O. Rate of infra-position of reimplanted ankylosed incisors related to age and growth in children and adolescents. *Dent Traumatol.* 2002; 18(1): 28-36.
61. Rohof ECM, Kerdijk W, Jansma J, Livas C, Ren Y. Autotransplantation of teeth with incomplete root formation: A systematic review and meta-analysis. *Clin Oral Investig.* 2018; 22(4): 1613-1624.
62. Akhlef Y, Schwartz O, Andreasen JO, Jensen SS. Autotransplantation of teeth to the anterior maxilla: A systematic review of survival and success, aesthetic presentation and patient-reported outcome. *Dent Traumatol.* 2018; 34(1): 20-27.
63. Malmgren B, Tsilingaridis G, Malmgren O. Long-term follow up of 103 ankylosed permanent incisors surgically treated with decoronation - a retrospective cohort study. *Dent Traumatol.* 2015; 31(3): 184-189.
64. Tsukiboshi M. Autotransplantation of teeth: Requirements for predictable success. *Dent Traumatol.* 2002; 18(4): 157-180.
65. Lin S, Schwarz-Arad D, Ashkenazi M. Alveolar bone width preservation after decoronation of ankylosed anterior incisors. *J Endod.* 2013; 39(12): 1542-1544.
66. Moffat MA, Smart CM, Fung DE, Welbury RR. Intentional surgical repositioning of an ankylosed permanent maxillary incisor. *Dent Traumatol.* 2002; 18(4): 222-226.
67. Dolanmaz D, Karaman AI, Pampu AA, Topkara A. Orthodontic treatment of an ankylosed maxillary central incisor through osteogenic distraction. *Angle Orthod.* 2010; 80(2): 391-395.
68. Nocini PF, De Santis D, Ferrari F, Bertele GP. A customized distraction device for alveolar ridge augmentation and alignment of ankylosed teeth. *Int J Oral Maxillofac Implants.* 2004; 19(1).
69. Ionta FQ, Gonçalves PSP, Honório HM, Oliveira GCd, Alencar CRBd, Santos NM, et al. Delayed tooth reimplantation with 4-year follow-up: The management of ankylosis during facial growth. *Gen Dent.* 2018; 66(3): 53-57.
70. Díaz JA, Jans GA, Zaror CE. Long-term evaluation and clinical outcomes of children with dental transplants in Temuco City, Chile. *Eur J Paediatr Dent.* 2014; 15(1): 6-12.

71. Kvint S, Lindsten R, Magnusson A, Nilsson P, Bjerklin K. Autotransplantation of teeth in 215 patients: A follow-up study. *Angle Orthod.* 2010; 80(3): 446-451.
72. Czochrowska EM, Stenvik A, Bjercke B, Zachrisson BU. Outcome of tooth transplantation: Survival and success rates 17-41 years posttreatment. *Am J Orthod Dentofacial Orthop.* 2002; 121(2): 110-119.
73. Czochrowska EM, Stenvik A, Album B, Zachrisson BU. Autotransplantation of premolars to replace maxillary incisors: A comparison with natural incisors. *Am J Orthod Dentofacial Orthop.* 2000; 118(6): 592-600.
74. Schropp L, Wenzel A, Kostopoulos L, Karring T. Bone healing and soft tissue contour changes following single-tooth extraction: A clinical and radiographic 12-month prospective study. *Int J Periodontics Restorative Dent.* 2003; 23(4).
75. Horvath A, Mardas N, Mezzomo LA, Needleman IG, Donos N. Alveolar ridge preservation. A systematic review. *Clin Oral Investig.* 2013; 17(2): 341-63.
76. Tonetti MS, Jung RE, Avila-Ortiz G, Blanco J, Cosyn J, Fickl S, et al. Management of the extraction socket and timing of implant placement: Consensus report and clinical recommendations of group 3 of the XV European Workshop in Periodontology. *J Clin Periodontol.* 2019; 46: 183-194.
77. Zitzmann NU, Özcan M, Scherrer SS, Bühler JM, Weiger R, Krastl G. Resin-bonded restorations: A strategy for managing anterior tooth loss in adolescence. *J Prosthet Dent.* 2015; 113(4): 270-276.
78. Moorrees CF, Fanning EA, Hunt EE, Jr. Age variation of formation stages for ten permanent teeth. *J Dent Res.* 1963; 42: 1490-502.
79. Andreasen JO, Paulsen HU, Yu Z, Bayer T, Schwartz O. A long-term study of 370 autotransplanted premolars. Part II. Tooth survival and pulp healing subsequent to transplantation. *Eur J Orthod.* 1990; 12(1): 14-24.



## Appendix 1

### Example of Search Strategy

Literature search was carried out using the following electronic databases: Medline, Pubmed, Cochrane Database of Systemic Reviews (CDSR) and Embase while full text journal articles were retrieved from these databases. The literature search was limited to human study, English language and published articles from inception of databases to June 2019.

### **Clinical Question: What is the effective and safe emergency management of avulsed permanent anterior teeth?**

1. TOOTH AVULSION/ (2372)
2. (tooth adj1 (avuls\* or dislocat\* or luxat\*)).tw. (575)
3. (teeth adj1 (avuls\* or dislocat\* or luxat\*)).tw. (541)
4. INCISOR/ (22398)
5. incisor\*.tw. (29357)
6. DENTITION, PERMANENT/ (1882)
7. ((adult or permanent or secondary) adj1 dentition).tw. (3207)
8. 1 or 2 or 3 or 4 or 5 or 6 or 7 (43548)
9. EMERGENCIES/ (40649)
10. emergenc\*.tw. (407865)
11. EMERGENCY TREATMENT/ (10752)
12. (emergency adj1 therap\*).tw. (701)
13. (emergency adj1 treatment\*).tw. (4675)
14. 9 or 10 or 11 or 12 or 13 (427169)
15. 8 and 14 (822)
16. limit 15 to (english language and humans and yr="2009 -Current") (278)

**Appendix 2****CLINICAL QUESTIONS**

- a) What is the effective and safe emergency management of avulsed permanent anterior teeth?
- b) What are the contraindications for replantation of avulsed permanent anterior teeth?
- c) What are the appropriate preoperative clinical and radiographic assessments of avulsed permanent anterior teeth?
- d) What are the prognostic factors for avulsed permanent anterior teeth?
- e) What are the indications and timing for root canal treatment for avulsed permanent anterior teeth?
- f) Are splinting and systemic antibiotics effective and safe in avulsed permanent anterior teeth?
- g) What is the follow-up protocol for replanted avulsed permanent anterior teeth?
- h) What are the treatment options of complications of replanted avulsed permanent anterior teeth?

## Appendix 3

**Main characteristics, efficacy and accessibility of each storage medium for avulsed permanent anterior teeth** <sup>31-33, level III</sup>

STORAGE MEDIUM	CHARACTERISTICS	EFFICACY	ACCESSIBILITY
Hank's Balanced Salt Solution (HBSS)	Physiological pH, osmolality and nutrients	Excellent	--
Viaspan®	Physiological pH, osmolality and favourable to cell growth	Excellent	--
Euro-Collins®	Physiological pH and hypothermal capacity	Excellent	--
Minimum Essential Medium (MEM)	Nutrients, antimicrobial property and growth factors	Excellent	--
Milk	Small bacterial contents, isotonic, physiological pH, osmolality, unique combination of growth factors and nutrients	Excellent	+
Propolis	Anti-inflammatory, antibacterial and antioxidant properties	Excellent	--
Green tea	Anti-inflammatory, antibacterial and antioxidant properties	Excellent	--
Egg white	Low microbial contamination, contains nutrients and water	Good	+
Coconut water	Sterile, natural product and contains nutrients	Good	+
Ricetral	Essential cells and nutrients	Good	+
Gatorade®	Low pH and hypertonic	Poor	+
Contact lens solution	Antimicrobial property, preservatives	Poor	+
Normal Saline	Physiological pH and osmolality	Poor	+
Water	Microbial contamination, hypotonic, non-physiological pH and osmolality	Very poor	++
Saliva	Microbial contamination, hypotonic, non-physiological pH and osmolality	Very poor	++

++ easily available, + available, - less available, -- least available

## Appendix 4

**DENTAL TRAUMA DATA COLLECTION FORM**

<b>Patient details</b>			
Name:			Identification Card (IC) No:
Age:	Gender:	Ethnic:	Hospital Registration No:
<b>General health</b>			
Medical history (including immunization and regular medication):			
Relevant Past Dental History:			
<b>General details of injury</b>			
Date:	Time:	Location	
Cause/Mechanism:			
Current complaint:			
Previous dental treatment received for this particular injury? (State any management ie tetanus injection, analgesics, antibiotics, radiographs, replantation etc)			
For tooth avulsion injury, please state:			
<ol style="list-style-type: none"> <li>1. Total extra-alveolar time:</li> <li>2. Dry time:</li> <li>3. Storage medium (type and time):</li> <li>4. Tooth maturity (open or closed apex):</li> </ol>			
<b>Presentation and nature of injury</b>			
Relevant extraoral presentation (E.g. Concomitant injury, basal bone fracture, soft tissue injury, etc.)			
Relevant general intraoral presentation (E.g. Oral hygiene, soft tissue injury, dento-alveolar fracture etc.)			



## Appendix 5

## Clinical and radiographic parameters to be recorded during review appointment

Date :

TOOTH (To include replanted avulsed and control tooth)						
<b>CLINICAL</b>	Sinus tract/ Abscess/ Swelling					
	Colour (Crown discoloration) * If yes, please state the colour of crown					
	Mobility (Grade 0-3)					
	Percussion Test a) Tenderness b) Metallic/Ankylotic sound					
	Sensibility Test a) Cold test b) Electric Pulp (EPT)					
	Periodontal a) Pocket depth b) Gingival recession c) Bleeding on probing					
	Occlusion a) Premature contact b) Extrusion c) Infra-occlusion					
<b>RADIOGRAPHIC</b>	Loss of lamina dura					
	Periapical radiolucency					
	Root resorption					
	Pulp obliteration					
	Immature tooth with open apex - Thickening of dentinal wall - Root growth - *Root stage (Stage 1-6 )					

Fill in the boxes as –ve for absent or +ve for present

\*Stage of root maturity according to Moorrees Classification 1963:<sup>78, 79</sup>

Stage 1 = R¼ or Root length ¼;

Stage 2 = R½ or Root length ½;

Stage 3 = R¾ or Root length ¾;

Stage 4 = RC or Root length complete;

Stage 5 = A½ or Apex ½ closed;

Stage 6 = AC or Apical closure complete

## Appendix 6

**Possible complications and expected timing of occurrence following replantation of avulsed permanent anterior teeth.**

No.	Complications	Expected timing of occurrence <sup>56</sup>	Findings	
			Clinical	Radiographic
1	Pulpal necrosis	2 weeks – 2 years	<ul style="list-style-type: none"> <li>• Symptomatic (pain/tender/swelling)</li> <li>• No respond to sensibility test</li> </ul>	<ul style="list-style-type: none"> <li>• No specific characteristics can be appreciated or</li> <li>• presence of periapical radiolucency</li> </ul>
2	Inflammatory resorption	5 months – 2 years	<ul style="list-style-type: none"> <li>• Symptomatic (pain/tender/swelling)</li> <li>• Presence of sinus/ abscess/ swelling</li> <li>• The tooth is mobile (grade &gt;1), possibly extruded</li> <li>• Tenderness to percussion</li> <li>• No respond to sensibility test</li> <li>• Crown discolouration</li> <li>• Periodontal pocket depth &gt;3mm, presence of bleeding on probing</li> <li>• Presence of gingival recession</li> </ul>	<ul style="list-style-type: none"> <li>• Loss of lamina dura</li> <li>• Presence of periapical radiolucency</li> <li>• Radiolucent saucershaped cavitation along the root surface</li> </ul>
3	Replacement resorption or ankylosis	6 months – 2 years	<ul style="list-style-type: none"> <li>• Asymptomatic</li> <li>• The tooth is immobile (grade 0)</li> <li>• No tenderness to percussion and percussion tone is high (metallic sound)</li> <li>• Infra-occlusion of the tooth in growing patient</li> </ul>	<ul style="list-style-type: none"> <li>• Loss of lamina dura and replacement of periodontal space with bone</li> <li>• Continuous replacement of root with bone</li> </ul>

## ACKNOWLEDGEMENTS

The members of the development group of these guidelines would like to express their gratitude and appreciation to the following for their contributions:

- CPG council
- Panel of internal and external reviewers
- Technical Advisory Committee for CPG for their valuable input and feedback
- Dr Mohd Aminuddin Mohd Yusof, and Dr Ainol Haniza binti Kherul Anuwar, CPG Unit, Malaysian Health Technology Assessment Section, Medical Development Division, Ministry of Health Malaysia
- All those who have contributed directly or indirectly to the development of the CPG

## DISCLOSURE STATEMENT

The panel members had completed disclosure forms. None held shares in pharmaceutical firms or acts as consultants to such firms. (Details are available upon request from the CPG Secretariat)

## SOURCES OF FUNDING

The development of the CPG on “**Management of Avulsed Permanent Anterior Teeth**” was supported financially in its entirety by the Ministry of Health Malaysia and was developed without any involvement of the pharmaceutical industry.











Oral Health Technology Section  
Oral Health Programme  
Ministry of Health Malaysia  
Level 5, Block E10, Precinct 1  
Federal Government Offices Centre  
62590 Putrajaya, Malaysia

ISBN 978-967-16632-5-7



9 789671 663257